



(RESEARCH ARTICLE)



Acute effect of the novel cadaver fixation and storage solution -Anatomical-biomechanical-microbiological study

Murat Sırrı AKOSMAN ¹, Fethi ERBÜLBÜL ¹, Recep KARA ^{2,*} and Abdurrahman Fatih FİDAN ³

¹ Department of Anatomy, Faculty of Veterinary Medicine, Afyon Kocatepe University, Afyonkarahisar, Türkiye.

² Department of Food Hygiene and Technology, Faculty of Veterinary Medicine, Afyon Kocatepe University, Afyonkarahisar, Türkiye.

³ Department of Biochemistry, Faculty of Veterinary Medicine, Afyon Kocatepe University, Afyonkarahisar, Türkiye.

World Journal of Advanced Research and Reviews, 2024, 23(03), 1250–1260

Publication history: Received on 26 July 2024; revised on 02 September 2024; accepted on 05 September 2024

Article DOI: <https://doi.org/10.30574/wjarr.2024.23.3.2709>

Abstract

Cadaver education is a golden standard in health sciences. It is aimed to purify the cadavers from microbes by subjecting them to chemicals and to be used for many years by terminating autolysis. As a result of literature searches, a solution consisting of a mixture of borax, nitrite-nitrate, glycerin, alcohol, and thyme oil was created. While seven sheep hearts were placed in this solution, seven were kept in 10% formaldehyde for two months for fixation and storage. At the end of the first ten days, it was observed that the discoloration of the heart in the solution was lower than the formalin fixation. In histological examinations, it was observed that there was no visual difference between the groups and the tissue could be examined at all magnifications. At the end of two months, insignificant microbial growth observed in the solution. While color changes were better than formaldehyde, texture profile analysis values were found to be closer to fresh heart. In histological examinations, in the solution group, although the tissue could be recognized at all magnifications, it was observed that cell nuclei were less stained at x100. It was concluded that this solution can be used mainly in short-term courses.

Keywords: Boron; Cadaver; Fixation; Formaldehyde; Heart

1. Introduction

The importance of cadaver education in training health science specialists is indisputable. Students work on cadavers in anatomy courses, make dissections and have ideas and information on three-dimensional images of organs and tissues. Cadaver education is very important not only in anatomy courses but also in various branches of medical education such as pathology and surgery [1]. In veterinary medicine, cadavers are used as materials in education and clinical research to gain clinical skills beyond anatomy courses [2]. In terms of education, a cadaver is desired to have the tissue softness of a living body. This softness is tried to be achieved in the solutions applied for cadaver fixation. When evaluating the quality of a cadaver, it must score full marks in criteria such as hardness, colour, smell and structure. The closer these criteria are to the real tissue, the higher the quality of cadaver identification [3].

The aim of cadaver preparation is firstly to stop autolysis and microbial reproduction of the cadaver. Thus, since the cadaver will be free from microorganisms, disease transmission to students and instructors will be prevented and it will be stored for many years without deterioration. A cadaver that is not well disinfected becomes a source of infection for teachers and students [1, 4]. Recently, the most commonly used fixative is formaldehyde, which has antibacterial and fungicidal properties. However, cadavers fixed in formaldehyde do not have the colour, softness and flexibility of fresh cadavers, even if they last for many years. Fixed cadavers cannot exhibit some of their natural characteristics such

* Corresponding author: Recep KARA ORCID ID: 0000-0002-9257-7506

as the flexible structure of the heart and vessels and the expansion of the lungs [1]. Even if protective equipment is used against formaldehyde gas, a colourless gas with a pungent odour at normal room temperature, it is dangerous for health. In addition to its harmful effects on the nervous system and digestive system, it also has negative effects on the reproductive system. It has been reported that exposure to formaldehyde disrupts the morphological structure of the testis and causes fertility problems [5]. It is an important carcinogen in addition to skin rashes, allergies, respiratory problems and environmental damage [1, 6]. The International Agency for Research on Cancer has declared formaldehyde as a class 1 carcinogen [7].

It has been reported that when formaldehyde in the environment reaches values between 0.5-2 ppm, measured in parts per million (ppm), it causes side effects such as irritation in the mucosa and watery eyes. According to the Japanese occupational health chamber, the formaldehyde rate in an environment should be below 0.5 ppm [8]. Mirabelli et al. [9] observed that the formaldehyde concentration of 1.8-2.4 ppm in the environment during cadaver dissection can increase up to 3.8 ppm during the lecture. He stated that this degree of exposure would lead to problems in the eyes and respiratory tract in the acute stage, followed by cancer in the nasal mucosa and genotoxicity in the lungs. Kunugita et al. [10] found that the values measured between 0.02-0.09 ppm in the laboratory before the anatomy lesson could increase up to 1-1.4 ppm during the lesson. They observed that these rates caused stinging and burning in the students' eyes, thirst, headache and fatigue. Tanaka et al. [8] reported that during anatomy dissections in the laboratory for 3 months, the concentration of formaldehyde in the environment reached up to 0.62 ppm and students had complaints similar to Kunigata et al. [10]. It has been observed that contact with the skin, apart from the respiratory tract, also causes allergic contact dermatitis, skin peeling and irritation [11, 12, 13].

For this reason, various solutions that can be used as cadaver storage solutions are being sought instead of formaldehyde [6]. The best known of these solutions is Thiel's solution [14]. Thiel's solution composed of A and B parts. Solution A consists of low amounts of formaldehyde, boric acid, ethylene glycol, ammonium nitrate and water, while solution B consists of ethylene glycol and 4-chloro-3-methylphenol. While the combination of these two solutions is used for cadaver fixation, a composition consisting of ethylene glycol, formaldehyde, B solution, ammonium nitrate, potassium nitrate, sodium sulfate and water is used to preserve the fixed cadaver [6, 14].

In cadavers fixed in Thiel's solution, it was found that the muscle and skin retained close to the texture and softness before death. However, as a result of the subsequent examination of the cadavers, it was observed that the Thiel solution caused degenerations in the muscle tissues. The reason for these degenerations was found to be boric acid as a result of various examinations [15, 16]. Akosman et al. [17] tried borax, the alkaline form of boron, as a cadaver preservation solution on muscle tissues instead of boric acid and obtained successful results [17].

Scientists have developed solutions other than Thiel's. A recent solution developed by Menon et al. [18] is a composition of 25% ethanol, 20% polyethylene glycol 400, 0.1% chloroxylenol, and 10% sodium nitrate with tap water to 100%. This solution was used as both a fixation and preservation solution on a group of animal cadavers consisting of two dogs, two cats, two sheep and two goats. Color changes, hardening, adhesion, deformation and microbiological growth in the cadavers were evaluated. Lombardero et al. [19] used saturated salt solution as an alternative solution. They applied this solution to cadavers for 6-8 hours and stored them in the same solution. Turan et al. [20] prepared a fixative and storage solution consisting of liquid foam soap, ethanol, citric acid, and benzalkonium chloride. Hardness, colour and odour changes and microbiological growth in cadavers were objectively evaluated for one year. Janczyk et al. [21] stated that nitrite salt solution with ethanol and Pluriol can be used instead of formaldehyde. Queiroz et al. [3] prepared a cadaver preparation solution by adding 5% glycerin to 150 mL/kg alcohol and 1% nitrite and, 1% sodium nitrate to 120mL/kg 20% sodium chloride.

In this study, a new and original cadaver fixation and preservation solution was tried to be created based on the chemicals used in the above studies. A combination of chemicals consisting of ethyl alcohol, borax, glycerin, nitrite-nitrate and thyme oil was used in the solution. Ethyl alcohol was used for cadaver identification, while borax was used as a substitute for boric acid. Glycerin was applied to the cadaver to maintain softness and joint mobility, while nitrite and nitrate were applied to maintain the red colour and have bacteriostatic effect. Thyme oil was preferred because of its antibacterial and antifungal properties. Sheep heart was used as cadaver to measure the effectiveness of the solution. It is known that the heart distributes blood throughout the body through blood vessels. The blood distributed throughout the body returns to the heart through blood vessels. Thus, while the heart distributes the substances that the body needs, such as oxygen and nutrients, to the body, it also transports the substances resulting from metabolic activities in the tissues to the liver, kidneys and lungs [22]. Thus, the effect of the solution on the internal organs was tried to be understood. The cadavers were analysed for colour and texture. Tissues were examined histologically on the tenth day and at the end of the study. The solution was also analysed for microbial growth at the end of the study.

2. Material and methods

2.1. Tissues

A total of 14 sheep hearts were used in this project, which was carried out with the aim of producing a detection and storage solution close to a healthy and fresh cadaver. Sheep hearts were obtained from the slaughterhouse and brought to the laboratory, quickly. The hearts brought to the laboratory were photographed and divided into two equal groups.

2.2. Solutions

Seven sheep hearts were placed in 10% formaldehyde solution used for cadaver preservation and the rest were placed in the experimental solution. Borax, nitrite, nitrate, glycerin, alcohol and thyme oil were used to prepare this solution. Firstly, 200 g borax, 5 g nitrate and 5 g nitrite were dissolved in 2 l distilled water. Then 50 ml of glycerin was dissolved in 1 litre of 96% ethanol and 50 ml of concentrated thyme oil was added to the prepared solutions and combined. The pH value of the prepared solution, which was 9.5, was adjusted to 7.5 using glacial acetic acid. The reason for this adjustment was that the Thiel solution had a similar pH value. After the pH of the solution was adjusted, the hearts were placed in it.

2.3. Analyses

The hearts in both groups were kept in the solutions in closed containers at room temperature for two months. During this period, the tissues were continuously checked and examined for the presence of any deterioration or degeneration. On the 10th day of the study, histological tissue follow-up was performed from the samples taken from the heart tissues. For this aim, the tissues were passed through graded alcohols and xylol and embedded in paraffin. The paraffin-embedded tissues were sliced with a microtome at a thickness of 5 micrometres and the sections were stained with haematoxylin-eosin stain. The stained tissue samples were photographed under light microscope.

At the end of the study, the hearts were removed from the solutions and photographed together with the sample brought from the abattoir. Comparisons were made in terms of hardness and colour differences between the cadavers before and after fixation. For texture profile analysis and determination of colour changes, 3cmx3cm samples were taken from hearts in both solutions and fresh heart tissue brought from the abattoir that day and placed in the following devices.

Texture profile analysis (TPA) was used to determine the hardness (hardness-N), springiness, cohesiveness and gumminess (gumminess-N) properties of the samples (Microstable TA.XT Plus, USA), and colour change CIE L* (darkness), a* (redness) and b* (yellowness) values were measured using Hunter-Lab ColorFlex (A60-1010-615 Model Colorimeter, HunterLab, Reston, VA). Before the measurements, the spectrophotometer was calibrated with white and black reference colours and L*, a*, b* values were obtained with three different readings. The pH of the storage solutions was evaluated by measuring the pH value of the storage solutions in buffer solutions of pH 4 and pH 7 with a standardised pH meter (Orion 420A, USA).

At the end of the study, heart tissue samples were taken and histological tissue follow-up was performed. Samples taken from the tissues for histological examination were examined under a light microscope. In routine histological follow-up, tissues were passed through graded alcohols, xylol and embedded in paraffin. The paraffin-embedded tissues were sliced with a microtome at a thickness of 5 micrometres and the sections were stained with haematoxylin-eosin stain. The stained tissue samples were photographed under a light microscope.

The solutions used in the study were examined for microbiological growth. For this purpose, 9 ml sterile peptone water was added to 1 ml samples taken from the solutions at the end of the study. Then, serial dilutions of 1:10 diluted sample were prepared and sowing was performed in the media [23, 24, 25].

2.4. Statistics

In the study, multiple readings with 3 repetitions were performed for variance analysis of the samples taken from the tissues for colour and texture analysis. The data obtained in the study were analysed by ANOVA test. The statistical significance for the difference between the groups was determined as 0.05.

3. Results

3.1. First Ten Days

3.1.1. Macroscopic Findings

The tissues placed in the solutions were monitored day by day. The tissues were removed from the solutions ten days after the start of the study and their condition was photographed and compared with the heart tissue brought fresh from the slaughterhouse that day (Figure 1). When the cadavers in formaldehyde solution were taken out of the container, it was observed that formaldehyde had an irritating odour and caused tearing in the eyes and difficulty in breathing. No irritating odour was observed in the solution group. On the contrary, when the lid of the container containing the hearts was opened, a pleasant thyme odour was emitted. There was also a marked loss of colour in the formaldehyde group.

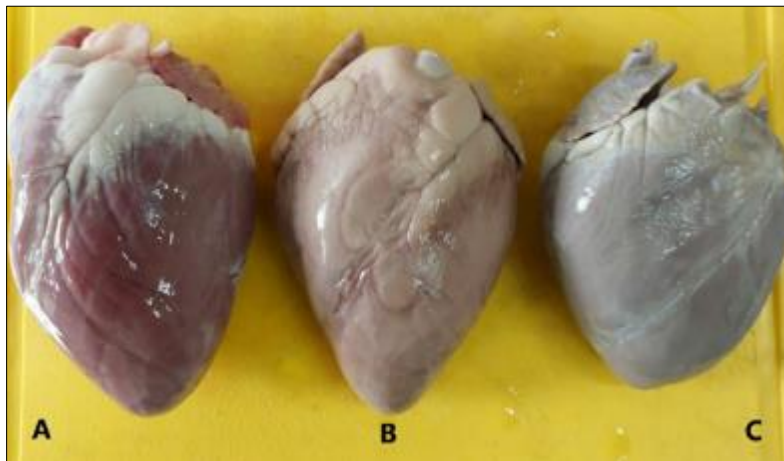


Figure 1 Comparison of fresh cadaver, solution and formaldehyde fixed hearts at day 10. A. Fresh heart tissue B. Heart tissue fixed in solution C. Formaldehyde fixed hearts

3.2. Microscopic Findings

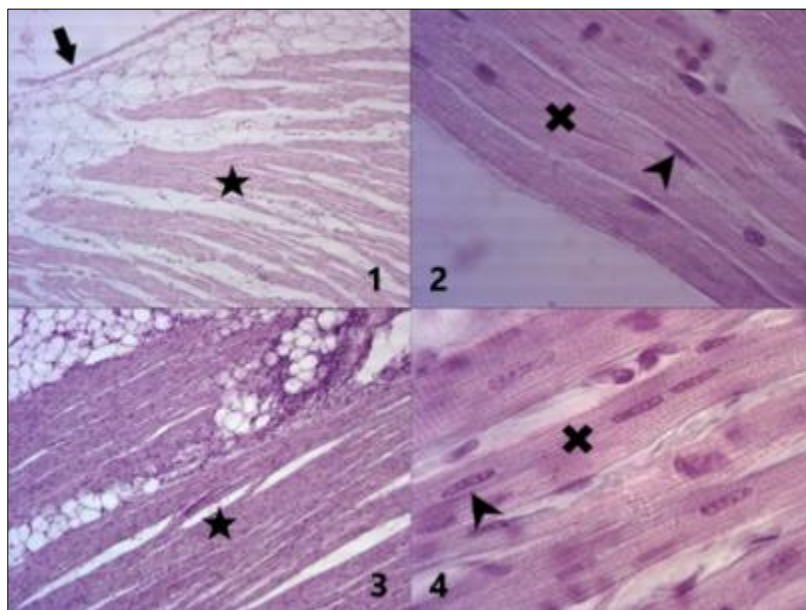


Figure 2 1. Sample taken from the heart of the formaldehyde group on the 10th day (x10) *: Myocardium Arrow: Epicardium 2. Sample taken from the heart of the formaldehyde group on day 10 (x100) x: Muscle fibres, Arrowhead: Cell nuclei 3. Solution group heart on the 10th day (x10) *: Myocardium 4. Sample taken from the heart of the solution group on day 10 (x100) x: Muscle fibres, Arrowhead: Cell nuclei

After these examinations, tissue samples were taken from the same regions of the hearts and histological process was performed. The hearts stained with haematoxylin-eosin stain were examined under light microscope at various magnifications and photographed. No structural difference was observed between the tissues examined. Cell nuclei were stained dark in both groups. The staining quality was as good as that of formaldehyde.

3.3. End of the Study

3.3.1. Macroscopic Findings

At the end of the study, the hearts in both groups were removed from the solutions and photographed side by side with fresh heart tissue taken from the slaughterhouse (Figure 3).

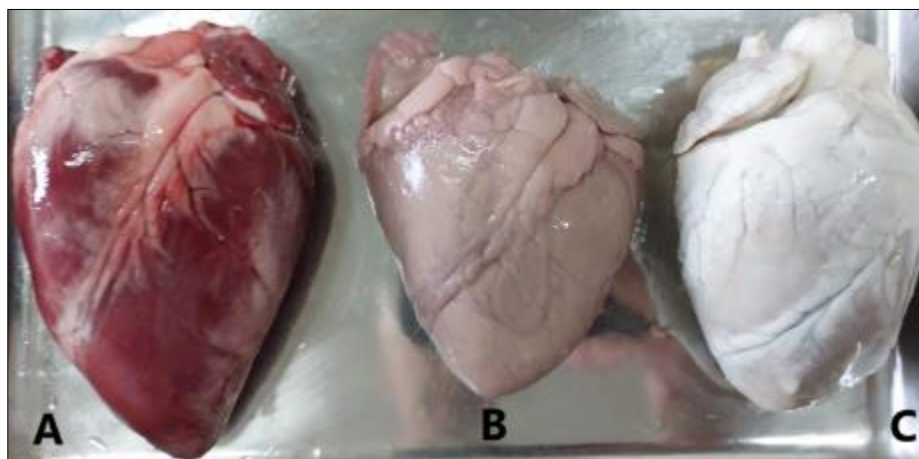


Figure 3 Appearance of the hearts at the end of the study. A. Fresh heart tissue B. Heart tissue fixed in solution C. Heart tissues fixed in formaldehyde It is noteworthy that the discolouration of the heart tissue in the formaldehyde group is high

When the lid of the container containing formaldehyde was opened, an eye and respiratory irritating odour of formaldehyde filled to the environment. In the solution group, there was a pleasant smell of thyme. The hearts in the formaldehyde group had lost their colour compared to the fresh cadaver. There was also a loss of colour in the solution group. However, the colour loss was not as pronounced as in formaldehyde (Table 1).

Table 1 Colour and pH Analysis Results of Heart Samples (n=3). L* (darkness); a* (redness); b* (yellowness) There is a statistical difference between groups with different letters in the same column

| Groups | L* | a* | b* | pH |
|--------------|-------------------------|------------------------|-------------------------|------------------------|
| Fresh | 36.52±0.57 ^c | 15.6±0.28 ^a | 8.78±0.11 ^c | 6.22±0.00 ^a |
| Formaldehyde | 75.57±1.44 ^a | 0.87±0.16 ^c | 10.21±0.44 ^b | 4.65±0.02 ^c |
| Solution | 59.72±0.59 ^b | 8.56±0.27 ^b | 16.99±0.18 ^a | 5.76±0.02 ^b |
| p | 0.001 | 0.001 | 0.001 | 0.001 |

When the hearts were compared in terms of texture, it was observed that the hearts in the formaldehyde group were very hard compared to both the hearts brought from the slaughterhouse and solution group. This hardness of the hearts in the formaldehyde group made it difficult to analyse their inner anatomical structures (Figure 4, Table 2).

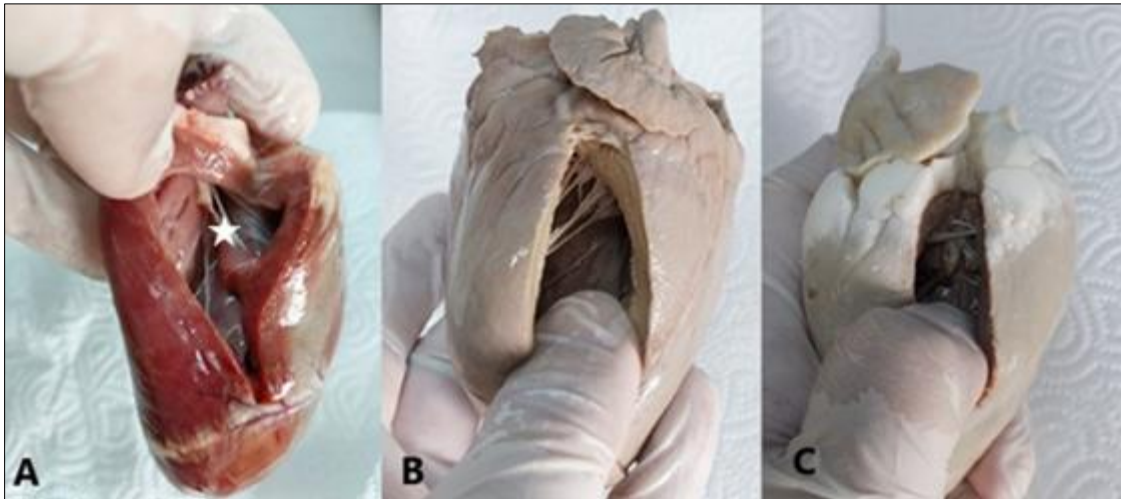


Figure 4 Picture showing the hardening of heart tissues. A. Fresh heart tissue B. Heart tissue fixed in the solution group C. Heart tissue fixed in the formaldehyde group. Chorda tendineae seen in the inner part of the hearts *

Table 2 Texture Analysis Results of Heart Samples (n=3). There is a statistical difference between the groups shown with different letters in the same column.

| Grups | Hardness | Elasticity | Stickiness | Gumminess |
|--------------|------------------------------|------------|------------|-------------------------------|
| Fresh | 2081.5±1321.59 ^b | 0.92±0.04 | 0.63±0.02 | 1294.98±800.55 ^b |
| Formaldehyde | 15986.9±3999.92 ^a | 0.90±0.01 | 0.72±0.07 | 11722.69±3183.33 ^a |
| Solution | 1202.5±823.97 ^b | 0.85±0.01 | 0.76±0.03 | 885.10±593.51 ^b |
| p | 0.009 | 0.276 | 0.215 | 0.012 |

In terms of colour and texture, the tissues in the formaldehyde group lost both their colour and softness. The hearts in this group were very hard, which made it difficult to open the heart and examine the vascular structures, chorda tendinea and ventricles. In the solution group, the colour of the hearts was close to that of fresh cadavers, although not as good as fresh cadavers, and the above-mentioned anatomical structures could be examined easily because they had a soft tissue (Figure 4-Tables 1-2).

3.3.2. Microscopic Findings

After this stage, small tissue samples were taken from the hearts and histological process was performed. No structural difference was observed between the tissues examined under light microscopy. While the structure of the heart was easily observed at low and high magnifications, it was noticeable that the cell nuclei in the solution group did not take the haematoxylin-eosin stain as well as those in the formaldehyde group.

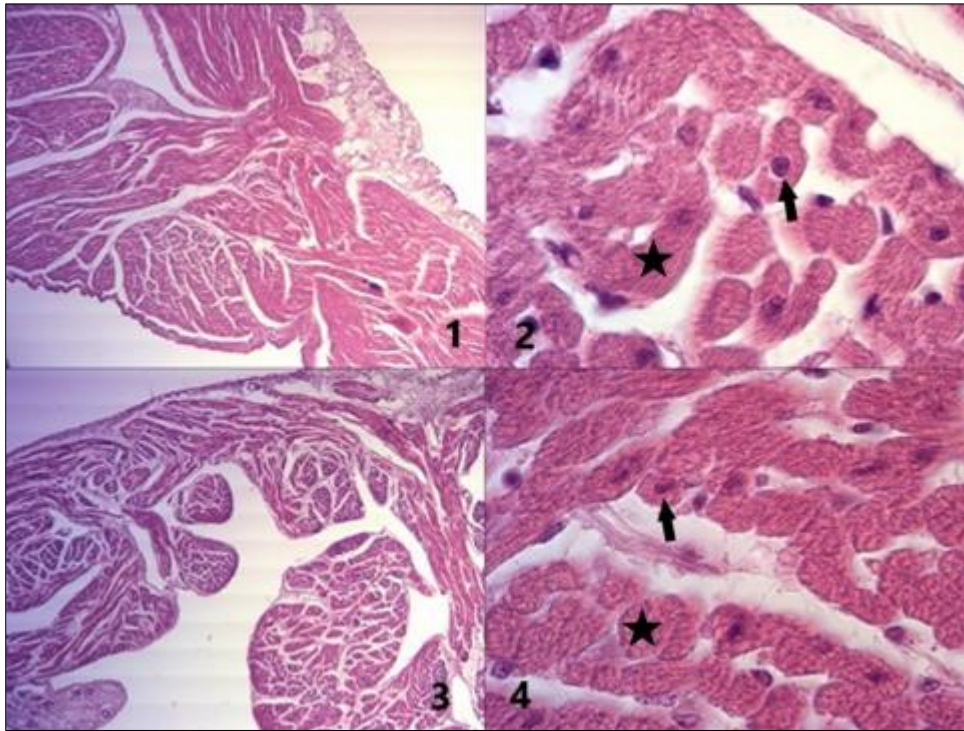


Figure 5 Figures taken from auricular (End of the study). 1. Formaldehyde group (x10) 2. Formaldehyde group (x100) *Muscle Fibres Arrow: Cell nuclei 3. Solution group (x10) 4. Solution group (x100) *Muscle fibres Arrow: Cell nuclei

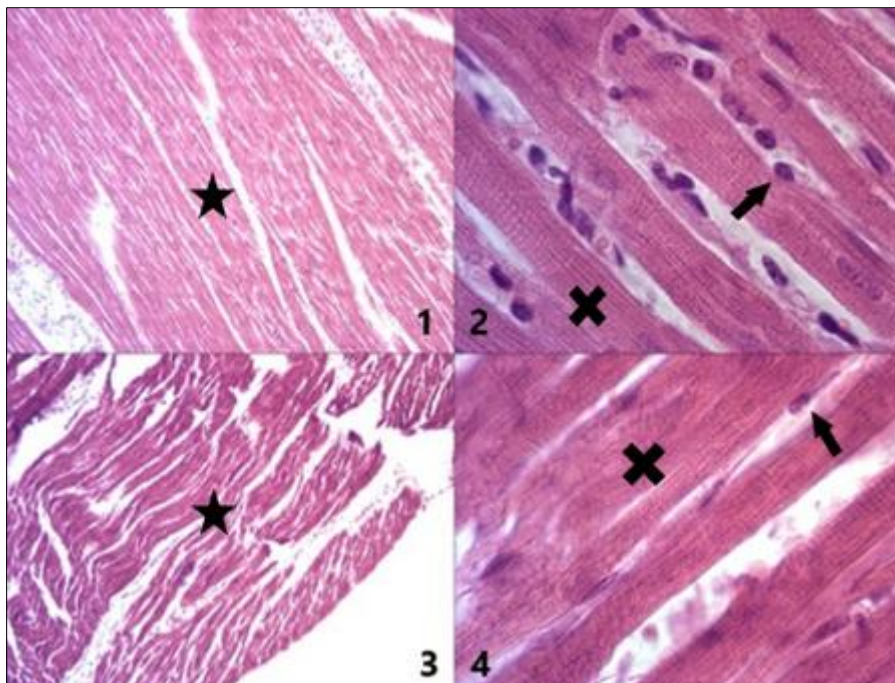


Figure 6 Figures from the myocardium (End of the study). 1. Formaldehyde group * (x10) 2. Formaldehyde group (x100) x: Muscle fibres Arrow: Cell nuclei 3. Solution group (x10) *Myocardium 4. Solution group (x100) x: Muscle fibres, Arrow: Cell nuclei

3.4. Microbial Growth

At the end of the study, the solution in which the tissues were stored was checked for microbial growth. Some microbial growth was observed in the solution compared to the formaldehyde group. However, this growth was not at a level to disrupt the tissue of the cadaver (Table 3-3).

Table 3 Microbiological Analysis of Heart Samples (n:3, log10)*<log 2.00 (cfu/ml)

| Grups | Total Number of Bacteria | Enterococcus | Coliform | Yeast/Mold | Enterobacteriaceae | Staphylococcus | E. coli |
|--------------|--------------------------|--------------|----------|------------|--------------------|----------------|---------|
| Formaldehyde | -* | - | - | - | - | - | - |
| Solution | 2,87 | 2,48 | 2,63 | 2,47 | 2,43 | 2,80 | - |

4. Discussion

While preparing the solution, borax, which is the alkaline form of boron, was preferred instead of boric acid, which is the acidic form of boron. Boron is a mineral taken into the body with daily food and drinks. It is abundant in nature in rocks, soil, coal and sea water [26]. Due to the degenerations caused by boric acid in muscles, Akosman et al. [17] tried borax solution instead of boric acid in the storage of muscle cadavers in their study. Muscle tissues fixed in formaldehyde were kept in borax containing solution for forty days. No histological difference was found between the muscle tissues kept in the solution and formaldehyde. There was no irritating odour in the muscle cadavers kept in solution and microbiological growth remained in trace amounts [17]. In the present study, no irritating odour of formaldehyde was found in the heart cadavers kept in solution, and no structural deterioration was observed histologically between the tissues. Microbial growth in the tissues was also found to be insignificant. When the colour and texture of the tissues were analysed, it was observed that they were close to fresh cadavers.

Menon et al. [18] applied the solution they prepared in their study to the bodies of farm animals such as cats, dogs, sheep and goats. The fixed bodies were observed for six months in terms of colour changes, hardness and microbial growth. Menon et al. [18] observed an increase in redness in cadavers other than cats. Menon et al. [18] stated that the solution prepared in their study slowed down the colour change. In addition Menon et al. [18] reported that sodium nitrite, which has antioxidant properties, prevents the deterioration process of the tissue by suppressing lipid oxidation and preserves the colour by interacting with myoglobin. However, nitrite causes an increase in yellow colour especially in adipose tissues [18].

Janczyk et al. [21] reported that nitrite salts cause colour changes in cadaver fixation due to added antioxidants. For this reason, they added ethanol and Pluriol (polyethylene glycol combination) to nitrite salts and tested this mixture on dog cadavers. In the final treatment, oregano oil was added to the mixture for a pleasant odour and ascorbic acid was added in small amounts as an antioxidant. All these chemicals were combined with tap water. Cadavers were stored in the same solution at 4-6°C after the procedure. They were reported that this type of application gave better results in animals with an open abdominal cavity, while in animals with a closed abdominal cavity, although the internal organs were not autolysed, they lost their natural appearance and microbial growth was detected in these cadavers.

Turan et al. [20] examined the possible positive effects of liquid soap on cadaver fixation. For this purpose, they prepared a solution consisting of liquid soap, ethanol, citric acid and benzalkonium chloride. They applied this solution to goat cadavers. These cadavers were kept in tanks filled with the same solution for one year. These cadavers used in the lessons on the disinfected tables. As a result of the examinations, it was determined that the cadavers were well preserved. It was stated that there was some odour, although not at disturbing levels. The cadavers were close to the anatomical appearance, hardness and elasticity of the fresh cadaver. Histologically, it was observed that the initially good appearance in the muscles started to deteriorate over time. In the present study, no disturbing odour was

encountered due to thyme odour. However, a limited number of microbial growth was observed. At the end of the second month, no degeneration was observed in the heart tissue, while histological examination of the heart showed that the cells were stained less pale compared to formaldehyde.

Menon et al. [18] stated that the main source of hardening in cadavers is dehydration. Menon et al. [18] reported that the solution they applied in some cadavers caused a slowly developing hardening in the muscle layer. Turan et al. [20] observed hardening in some cadavers at the end of one year. Menon et al. [18] detected that the reason for hardening in cadavers in their study may be due to ethanol in the composition of the solution. However, it has been previously found that glycerin added to cadaver preparation solutions causes cadavers to remain soft and allows even joint movements that are not seen in cadavers fixed with formaldehyde [6]. In the present study, it was observed that formaldehyde caused a high rate of hardening, which made it impossible to examine the internal structures of the heart. The hardness values of the heart tissues kept in the solution prepared by us were found to be very close to the values of fresh cadavers. Thus, students will work on cadavers that have a softness closer to the real softness of the heart than formaldehyde, and they will understand the natural structure of the heart more easily. They will examine the internal structures more easily and it will be easier to understand and learn the heart. The reason why the heart remains so soft may be due to the glycerin added to the solution.

Thyme oil is also known to have a very high antimicrobial activity compared to most vegetable oils [27]. In their study, Cengiz et al. [28] studied the protection of carvacrol, the main component of thyme oil, against the damage caused by cyclophosphamide, which is frequently used in the treatment of cancer and non-malignant diseases but causes cytotoxicity in tissues, on the reproductive system and emphasised that thyme oil has antioxidant and cell protective effects. For this reason, he stated that carvacrol can play an important role in reducing the side effects of chemotherapeutics. Menon et al. [18] did not find any microbial growth except for one cadaver in their study. He stated that the solution they developed can be safely used in cadaver detection for six months. Turan et al. [20] also mentioned the presence of bacterial growth, but observed that yeast and mould did not grow at all. In the present study, cadavers were taken to the external environment continuously, and examined by students and professors under laboratory conditions. In other words, microbial contamination was desired. Despite this, a low amount of microbial growth was observed in the solutions. This did not cause any visual signs of deterioration in the cadavers. This type of protection may be due to the antioxidative and antimicrobial activity of thyme oil.

Queiroz et al. [3] developed a solution for use in short-term courses, dissection or surgical lectures. The solution was a combination of ethanol, glycerine, sodium chloride, nitrite and sodium nitrate. The cat cadavers subjected to this solution were stored in vacuum packs at 0-4°C for seven days. He stated that the combination of glycerin and ethyl alcohol facilitated joint movements more than formaldehyde fixation. In the microbiological examination at the end of the seventh day, it was observed that aerobic and anaerobic bacteria grew, but this growth was not at a rate that would cause deformations in the cadaver. They stated that the cadavers kept in the solution gave results like fresh cadavers in the stretching tests on the skin and intestine and did not statistically differ.

5. Conclusion

In conclusion, in this study, a healthier solution was used as an alternative to formaldehyde fixation, which is frequently used in medical faculties and is known to be harmful to health. It was observed that the solution could be safely used in short-term courses or histological studies requiring short-term fixation. At the end of two months, it was found that the discolouration of the hearts increased, although not as much as in the formaldehyde group, but the hardness was close to the hardness of the fresh cadaver. This made it possible to observe the internal structures of the heart. In histological staining, it was seen that the structural features of the tissue were easily selected. At high magnifications such as 100x, it was observed that cell nuclei were recognised, but the solution group received less stain. Although the cadavers kept in the solution were continuously contaminated with the external environment, a trace amount of microbial growth was observed in the solution. Thyme oil, which has antimicrobial and fungicidal properties, was also found to cause a pleasant odour. It is thought that this solution prepared by combining chemicals that are less harmful to human health than formaldehyde has a generally positive effect on cadavers and can be used safely in short-term courses. However, there is a need for further studies on the solution.

Compliance with ethical standards

Acknowledgments

This study is funding by the Afyon Kocatepe University Scientific Research Project Units (22.SAĞ.BİL.24).

Disclosure of conflict of interest

No conflict of interest to be disclosed.

Author Contributions

Murat Sırrı Akosman contributed to the study conception, design and wrote the manuscript. Material preparation, data collection, and analysis were performed by Murat Sırrı Akosman, Abdurrahman Fatih Fidan and Fethi Erbülbül. Recep Kara made the microbiological analysis. Murat Sırrı Akosman wrote the manuscript, and all authors commented the document and approved the final manuscript.

References

- [1] Balta JY, Cronin M, Cryan JF & O'Mahony SM. 2015. Human preservation techniques in anatomy: A 21st century medical education perspective. *Clin Anat* 28: 725-734.
- [2] Varner C, Dixon L & Simons MC. 2021. The past, present, and future: a discussion of cadaver use in medical and veterinary education. *Front. Vet. Sci.* 8:720740. doi: 10.3389/fvets.2021.720740
- [3] Queiroz ABPS, Rodrigues A, Cardozo MV, Costa NTB, Soares LG, Fehis ADS & Oliveira FS. 2022. Biomechanical and microbiological analysis of embalmed cats - acute effect of conservation. *An Acad Bras Cienc.* 7:94(1):e20201583.
- [4] Arluke A. 2004. The use of dogs in medical and veterinary training: understanding and approaching Student uneasiness. *J Appl Anim Welf Sci* 7: 197-204.
- [5] Han SP, Zhou DX, Lin P, Qin Z, AN L, Zheng LR, & Lei L. 2015. Formaldehyde exposure induces autophagy in testicular tissues of adult male rats. *Environmental toxicology.* 30(3): 323–331.
- [6] Denis-Rodriguez E & Aguirre-Gutiérrez AA. 2018. Thiel Soft-Fix method for long term preservation. *Rev Mex Med Forense.* 3(2):91-98.
- [7] IARC. 2006. Formaldehyde, 2-butoxyethanol and 1-tert-butoxypropan-2-ol. *IARC Monogr Eval Carcinog Risks Hum.* 88:1–478.
- [8] Tanaka K, Nishiyama K, Yaginuma H, Sasaki A, Maeda T, Kaneko Sy, Onami T & Tanaka M. 2003. Formaldehyde exposure levels and exposure control measures during an anatomy dissecting course. *Kaibogaku zasshi. Journal of Anatomy.* 78(2): 43–51.
- [9] Mirabelli MC, Holt SM & Cope JM. 2011. Anatomy laboratory instruction and occupational exposure to formaldehyde. *Occupational and Environmental Medicine.* 68(5): 375–378.
- [10] Kunugita N, Nakashima T, Kikuta A, Kawamoto T, & Arashidani K. 2004. Exposure to formaldehyde during an anatomy dissecting course. *Journal of UOEH.* 26(3): 337–348.
- [11] Suruda A, Schulte P, Boeniger M, Hayes RB, Livingston GK, Steenland K, Stewart P, Herrick R, Douthit D & Fingerhut MA. 1993. Cytogenetic effects of formaldehyde exposure in students of mortuary science. *Cancer Epidemiol Biomarkers Prev.* 2: 453–60.
- [12] Mizuki M & Tsuda T. 2001. Relationship between atopic factors and physical symptoms induced by gaseous formaldehyde exposure during an anatomy dissection course. *Arerugi = [Allergy];* 50(1): 21–28.
- [13] Takahashi S, Tsuji K, Fujii K, Okazaki F, Takigawa T, Ohtsuka A & Iwatsuki K. 2007. Prospective study of clinical symptoms and skin test reactions in medical students exposed to formaldehyde gas. *The Journal of dermatology.* 34(5): 283–289.
- [14] Thiel W. 1992. The preservation of the whole corpse with natural color. *Ann Anat.* 174(3): 185-95.
- [15] Brenner E. 2014. Human body preservation – old and new techniques. *J Anat* 224:316-344.
- [16] Türkmen R, Demirel HH, Akarca G & Akosman MS. 2017. The investigation of potential preservative effect of boric acid on formalin fixed striated muscle tissues. *Kocatepe Veterinary Journal.* 10(4): 317-321.
- [17] Akosman MS, Kara R & Fidan AF. 2022. Preservation of muscle tissue with a formaldehyde-free borax solution for gross anatomy lessons. *World Journal of Advanced Research and Reviews* 16(03): 390–395.

- [18] Menon P, Aldarwich A, Hamdan L, Hammoud M & Aıyan AA. 2021. Novel formaldehyde-free embalming fluid formulation for long-term preservation of cadavers for anatomy teaching. *Emirates Journal of Food and Agriculture*. 33(9): 718-725
- [19] Lombardero M, Yllera MM, Costa-E-Silva A, Oliveira MJ & Ferreira PG. 2017. Saturated salt solution: a further step to a formaldehyde-free embalming method for veterinary gross anatomy. *Journal of Anatomy*. 231(2): 309–317.
- [20] Turan E, Gules O, Kılımcı FS, Kara ME, Dilek OG, Sabancı SS & TATAR M. 2017. The mixture of liquid foam soap, ethanol and citric acid as a new fixative-preservative solution in veterinary anatomy. *Annals of Anatomy*. 209: 11–17.
- [21] Janczyk P, Weigner J, Luebke-Becker A, Kaessmeyer S & Plendl J. 2011. Nitrite pickling salt as an alternative to formaldehyde for embalming in veterinary anatomy--A study based on histo- and microbiological analyses. *Annals of anatomy*. 193(1): 71–75.
- [22] Türkmenoğlu İ. Editor. 2022. *Evcil Hayvanlarda Veteriner Anatomi*. Medipres. Türkiye. pp: 471-481
- [23] ISO (International Standard Organisation). 2003. International Standard Organisation (ISO 4833), Horizontal Method for the Enumeration of Microorganism. Colony Count Technique at 300C.
- [24] ISO (International Standard Organisation). 2004. Microbiology of food and animal feeding stuffs — Horizontal methods for the detection and enumeration of Enterobacteriaceae — Part 2: Colony-count method.
- [25] ISO (International Standard Organisation). 2008. International Standard Organisation (ISO 21527), Microbiology of food and animal feeding stuffs — Horizontal method for the enumeration of yeasts and moulds.
- [26] Kabu M & Akosman MS. 2013. Biological Effects of Boron. In: Whitacre, D. (eds) *Reviews of Environmental Contamination and Toxicology*. 225: 57-75.
- [27] Turhan S & Tural S. 2017. Antimicrobial and antioxidant properties of thyme (*Thymus vulgaris* L.), rosemary (*Rosmarinus officinalis* L.) and laurel (*Lauris nobilis* L.) essential oils and their mixtures. *Gıda*. 42 (5): 588-596.
- [28] Cengiz M, Tekin Y, İnal B & Ayhancı A. 2017. Protective effects of carvacrol, essential composition of thyme plant, on cyclophosphamide-induced reproductive system damage on rats. *Turkish Journal of Agricultural Research* 4(2): 171-175