

## A review of different separator placement techniques for Hall crowns, and the introduction of a novel technique utilising rubber dam clamp forceps

Ishfaq Khan \*

*Midlands Partnership NHS Foundation Trust, Dental Services, St George's Hospital, Staffordshire, UK.*

World Journal of Advanced Research and Reviews, 2022, 16(01), 266–270

Publication history: Received on 04 September 2022; revised on 10 October 2022; accepted on 13 October 2022

Article DOI: <https://doi.org/10.30574/wjarr.2022.16.1.1013>

### Abstract

Hall crowns are a simple technique used in paediatric dentistry to treat restorable caries in primary molars in patients who are unwilling to accept conventional restorations. The use of Hall crowns has increased significantly due to the acceptance of the technique, and it is now commonly taught to dental undergraduates in the UK. Separator placement for Hall crowns can be difficult and may sometimes prevent Hall crowns from being utilised. This article describes the advantages and disadvantages of using rubber dam clamp forceps for the placement of separators for Hall crowns in comparison to other well-known methods.

**Keywords:** Hall crowns; Hall technique; Separator placement; Rubber dam clamp forceps; Dental caries

### 1. Introduction

Caries is a very common condition in children, often leading to pain, infection, disrupted growth, lost education, and difficulty with socialising [1]. Children who are uncooperative for dental care often require general anaesthesia for dental treatment, which can be associated with morbidity or even, in rare cases, mortality. Extraction of the primary dentition is the most common reason for young children to have a general anaesthetic in the UK, and it has a significant financial burden for the NHS [2]. Therefore, methods that can prevent caries and its progression and can be used in uncooperative or patients with reduced cooperation can significantly reduce the morbidity associated with general anaesthesia and caries.

Caries control in dentistry has changed significantly with a move towards a more minimal invasive approach. Initially, it was thought that all caries must be removed before restoration, but it is now widely accepted that partial caries removal such as atraumatic restorative technique (ART), and stepwise excavation (in particular in deep carious cavities with a risk of pulpal exposure) are effective [3]. Other methods of caries control have also gained acceptance including silver diamine fluoride and the silver modified atraumatic restorative technique (SMART), both of which can be completed in a single visit and do not require local anaesthesia [4]. The major disadvantage of treatments that use silver diamine fluoride is the permanent black staining that occurs.

The utilisation of Hall crowns as a viable restorative option for carious primary molars has gained popularity, in particular in the UK and during the COVID-19 pandemic as it is not considered an aerosol generating procedure. Several systematic reviews have shown the success of Hall crowns in comparison to other techniques, including stainless steel crowns, which require crown preparation [5, 6, and 7]. Hall crowns have few contraindications but include insecure airway, allergy to nickel, and patients at risk of bacterial endocarditis. The disadvantages of Hall crowns include the need (in most cases) for separators, poor aesthetics, and increased clinical time (2 visit technique).

\* Corresponding author: Ishfaq Khan

Midlands Partnership NHS Foundation Trust, Dental Services, St George's Hospital, Staffordshire, UK.

## 2. Material and methods

This article was completed after consulting up to date literature on this topic including relevant textbooks, systematic reviews and guidelines on the Hall technique.

## 3. The Hall technique

The Hall technique is only indicated for primary molars with caries restricted to dentine. Teeth with a history of irreversible pulpitis or dental infection are not suitable for Hall crowns [8]. The technique involves no local anaesthesia, no need for pre-treatment (e.g. silver diamine fluoride), and no need for caries removal. However, it is advised that a full clinical history and radiographs be performed.

In order to create space for Hall crowns, separators are used both mesially and distally of the tooth. Current techniques for separator placement include dental floss, orthodontic separator placing pliers, and mosquito forceps (although Spencer Wells forceps may be used in a similar manner). Table 1 shows the advantages and disadvantages of each of these techniques.

**Table 1** Advantages and disadvantages of different techniques for separator placement

Technique for separator placement	Advantages	Disadvantages
Dental floss	Cheap. No extra equipment is required. Most commonly taught technique. Less risk of damage to adjacent teeth or tissues as you are not using dental instruments for the placement of separators.	It can take more time than other techniques. It is more difficult to extend the separator compared to other techniques. Downward pressure is more difficult to apply. More technique-sensitive than using orthodontic separator placing pliers and mosquito forceps.
Orthodontic separator placing pliers	Allows easier placement and extension of separators. Quicker than using floss.	More expensive than floss. Extra equipment is required. Not all practices will have orthodontic instruments (may be limited to specialist orthodontic practices).
Mosquito forceps	Allows easier extension of separators. Quicker than using floss.	More expensive than floss. Risk of possible damage to the separator from forceps. Downward pressure is more difficult to apply. It requires two forceps. It may be difficult in patients who have a small mouth opening. Not all dental practices will have mosquito forceps.

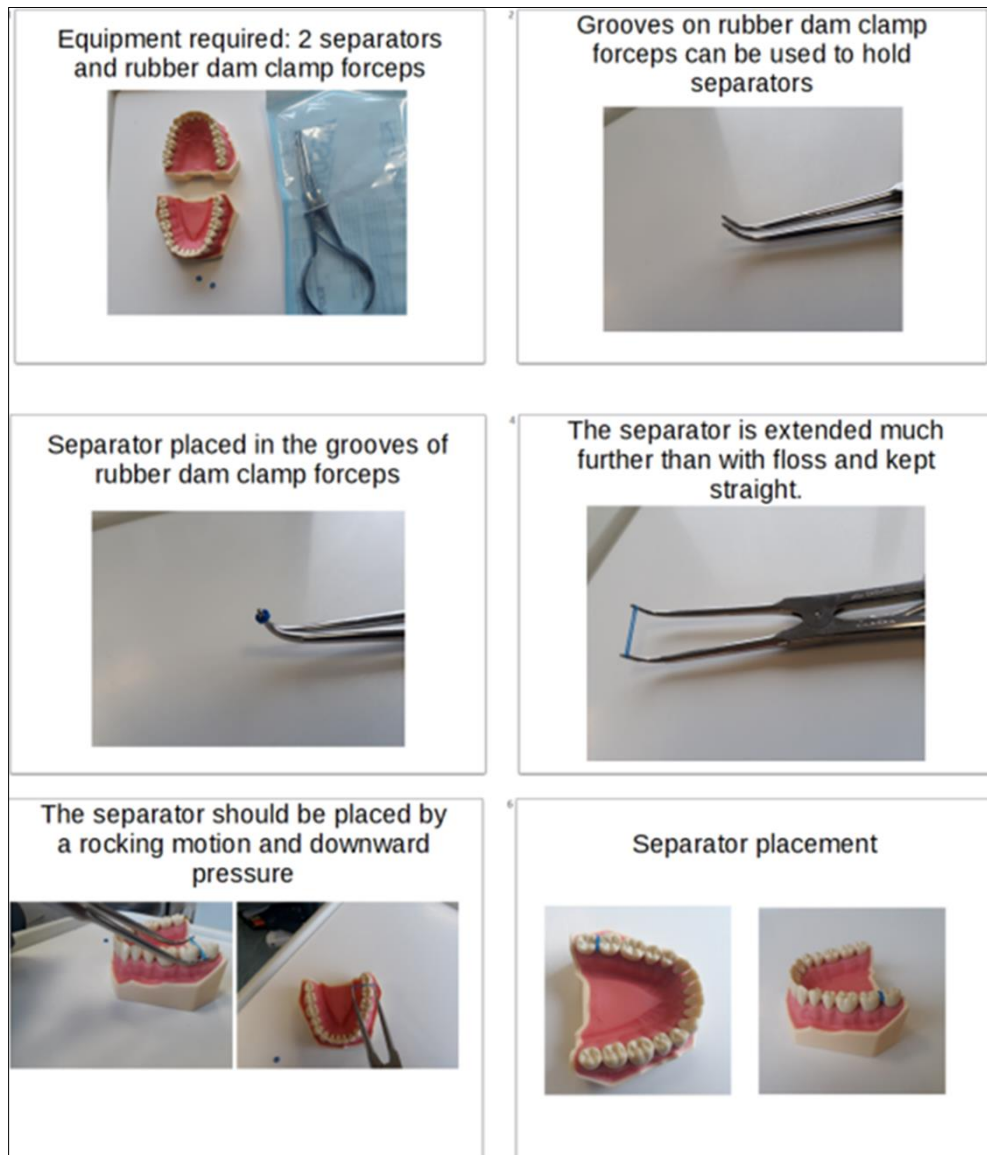
## 4. Rubber dam clamp forceps for separator placement

Rubber dam has many indications in dentistry and it is utilised for any clinical situation which requires moisture control or airway protection. Most commonly, this includes root canal therapy, composite restorations, fissure sealants, or the management of deep carious lesions. Therefore, most dental practices will likely have rubber dam clamp forceps as part of their armamentarium.

Rubber dam clamp forceps can also be used effectively to place separators for Hall crowns, and this technique is described below (see Figure 1) [9].

#### 4.1. Equipment

- Rubber dam clamp forceps (the author advocates using Stokes rubber dam clamp forceps).
- Separators.



**Figure 1** Technique for separator placement using rubber dam clamp forceps

#### 4.2. Technique

- Place the separator in the grooves on the rubber dam clamp forceps.
- Extend the rubber dam clamp forceps so that the separator is just wide enough to seat comfortably between the interdental space.
- Ensure the separator has not moved from within the groove or torn, and the separators should be straight and not twisted.
- The rubber dam clamp forceps are inverted for separator placement.
- Place the separator interdentially using a rocking motion and applying downward pressure simultaneously. Movement should be controlled and care must be taken to not apply excessive downward pressure, which can lead to soft tissue injuries.
- Close the rubber dam clamp forceps and remove them from the mouth.

### 4.3. Advantages

- Shorter learning curve than using other techniques, as most dentists are already accustomed to using rubber dam clamp forceps.
- The separator is held straight and is not twisted, making it easier to place, with greater downward pressure possible compared to floss.
- The separator can be stretched more and with less effort compared to using floss.
- Separator placement is achieved much more quickly than with using other techniques.
- It may be more effective in patients with smaller mouths as only the rubber dam clamp forceps need to be placed inside the mouth.
- The rubber dam clamp forceps can also be used to remove the separator if required.
- The technique may be more suitable for patients with a gag reflex.

### 4.4. Disadvantages

- Some paediatric or special care patients may find the rubber dam clamp forceps threatening compared to floss. The author refers to the rubber dam clamp forceps as 'rubber band stretchers'.
- The rubber dam clamp forceps would need to be sterilised prior to each patient.
- If the separator is stretched excessively, there can be more of the separator above the crown, and therefore, this may become an annoyance to the patient. This can be overcome by measuring the buccal-lingual width of the teeth (to receive separators) and using this information before separator placement.
- There is a risk of damage to adjacent teeth or tissue with sudden movements from the patient or incorrect technique

---

## 5. Conclusion

Hall crowns are a useful technique for paediatric patients who are dentally anxious and not cooperative for conventional restorations on teeth which do not have pulpal caries. Separator placement for Hall crowns may be difficult to complete, particularly when there are tight contacts, abnormal anatomy, or reduced cooperation from the patient. Rubber dam clamp forceps can be used effectively for separator placement and provide several advantages compared to the other techniques (especially floss) reported in the literature. However, the technique requires careful patient selection and may not be suitable for all patients.

---

## Compliance with ethical standards

### *Disclosure of conflict of interest*

The author declares no conflict of interest.

---

## References

- [1] Harper R, Nevill A, Senghore N, Khan I. Socioeconomic and ethnic status of two-and three-year-olds undergoing dental extractions under general anaesthesia in Wolverhampton, 2011-2016. *British Dental Journal*. 2019; 226(5):349-353.
- [2] Royal College of Surgeons of England. The State of Children's Oral Health in England [Internet]. London: Faculty of Dental Surgery; 2015 [cited 2022 Jun 03]. Available from: <https://www.rcseng.ac.uk/-/media/files/rcs/about-rcs/government-relations-consultation/childrens-oral-health-report-final.pdf>
- [3] Kidd EA, Fejerskov O. *Essentials of Dental Caries*. 4th ed. New York: Oxford University Press; 2016.
- [4] Innes N, Robertson M, Seeballuck C, Pinheiro Araujo, M. Restorative paediatric dentistry. In: Cameron AC, Widmer RP, eds. *Handbook of Pediatric Dentistry*. 5th ed. Edinburgh: Elsevier Health Sciences; 2021.
- [5] Badar SB, Tabassum S, Khan FR, Ghafoor R. Effectiveness of Hall technique for primary carious molars: a systematic review and meta-analysis. *International Journal of Clinical Pediatric Dentistry*. 2019; 12(5):445-452.
- [6] Saadun SW, Wafa T. Acceptability of atraumatic restorative treatment and Hall Technique among children, parents, and general dental practitioners: a systematic review and meta-analysis. *Quintessence International*. 2022; 53(2):156-169.

- [7] Hu S, BaniHani A, Nevitt S, Maden M, Santamaria RM, Albadri S. Hall technique for primary teeth: A systematic review and meta-analysis. *Japanese Dental Science Review*. 2022; 58:286-297.
- [8] Innes N, Evans D, Stewart M, Keightley A. The Hall Technique Guide V4 [Internet]. UK: University of Dundee; 2015 [cited 2022 Aug 30]. Available from: [https://upload.wikimedia.org/wikipedia/commons/9/91/HallTechGuide\\_V4.pdf](https://upload.wikimedia.org/wikipedia/commons/9/91/HallTechGuide_V4.pdf)
- [9] Khan I. Hall technique. *British Dental Journal*. 2021; 231(4):206